

# Effect of *Stichopus hermanii* extract on interleukin-6 levels in a high-fat diet-induced rat model of inflammation

Diah Purwaningsari<sup>1\*</sup>, Sihning Endah J. Tehupuring<sup>1</sup>, Nita Pranitasari,<sup>1</sup> Lestari Dewi<sup>2</sup>

<sup>1</sup>Department of Anatomy and Histology, Faculty of Medicine, Hang Tuah University, Surabaya, 60111, Indonesia

<sup>2</sup>Department of Pharmacology, Faculty of Medicine, Hang Tuah University, Surabaya, 60111, Indonesia

\*Corresponding Author: [diah.purwaningsari@hangtuah.ac.id](mailto:diah.purwaningsari@hangtuah.ac.id)

Received: 07 January 2026 / Accepted: 23 April 2026

**ABSTRACT:** Atherosclerosis is a major contributor to cardiovascular diseases and is increasingly recognized as a chronic low-grade inflammatory disorder involving oxidative stress and immune-mediated mechanisms. Interleukin-6 (IL-6) is a key proinflammatory cytokine that links oxidative stress and immune responses and has been widely associated with the progression of inflammation-related vascular conditions and the acceleration of atherosclerosis. The adverse effects of current pharmaceuticals have driven interest in herbal alternatives with fewer side effects. Sea cucumbers are recognized as potent biomedical resources with bioactivities against atherosclerotic pathways. This study aimed to identify the effects of *Stichopus hermanii* extract on IL-6 levels in a rat model of atherosclerosis induced by a high-fat diet. An experimental in vivo study utilizing a post-test-only control group design was performed on 32 Wistar rats, categorized into four groups: negative control (standard diet), positive control (high-fat diet), and two treatment groups administered *Stichopus hermanii* extract at dosages of 35 mg and 40 mg per 200 g body weight. IL-6 concentrations were markedly increased in rats subjected to a high-fat diet compared to those in the conventional diet group ( $p < 0.05$ ). *Stichopus hermanii* extract at both dosages markedly diminished IL-6 concentrations compared to the positive control group. The 40 mg dose reinstated IL-6 levels to those similar to the negative control group, signifying a dose-dependent anti-inflammatory effect. The extract of *Stichopus hermanii* successfully regulated IL-6 levels in rats with atherosclerosis induced by a high-fat diet, indicating its potential as a natural anti-inflammatory and cardioprotective agent for managing atherosclerosis.

**KEYWORDS:** Atherosclerosis; interleukin-6; sea cucumber; *Stichopus hermanii*.

## INTRODUCTION

Cardiovascular diseases (CVDs) are the leading cause of death worldwide and significantly contribute to disability. In 2019, an estimated 18.6 million people died from CVDs worldwide. Atherosclerosis refers to the thickening or stiffening of the arterial walls due to the accumulation of lipids, cholesterol, and other deposits. Atherosclerotic conditions, such as coronary heart disease and stroke, account for approximately 85% of all CVD-related fatalities. While death rates are falling more quickly in high-income countries than in low- and middle-income countries, significant inequalities persist even within countries, tied to socioeconomic status, ethnicity, and sex. Achieving an equitable global distribution of CVD prevention, diagnosis, and treatment remains a challenge. Limited access to adequate and equitable healthcare services for CVDs can delay CVD diagnosis and increase premature death from CVD [1].

Atherosclerosis is a chronic inflammatory disorder and a major underlying factor of stroke and coronary heart disease. It is characterized by the presence of plaques within the intimal layer and the buildup of cholesterol deposits within the arterial walls. The condition involves two main processes: atherosis, which refers to lipid accumulation accompanied by macrophage infiltration, and sclerosis, which entails the formation of a fibrotic layer composed of connective tissue, smooth muscle cells, and leukocytes [2]. Atherosclerosis was initially understood as a condition driven by lipoprotein retention in the intimal area of the arteries. Scavenger receptor-mediated phagocytosis modifies and collects retained LDL. As a result of this process, fatty infiltrates with accumulated inflammatory leukocytes that macroscopically resemble plaques continue to develop. Plasma cholesterol, LDL cholesterol, and apolipoprotein levels, especially apolipoprotein B (ApoB) levels, are all closely correlated with clinical atherosclerosis [3].

**How to cite this article:** Purwaningsari D, Tehupuring S, Pranitasari N, Dewi L. Effect of *Stichopus hermanii* extract on interleukin-6 levels in a high-fat diet-induced rat model of inflammation. *Jurnal Ilmu Kefarmasian Indonesia*. 2026 April 30; 2026(1): 38-48.

In contrast, recent research has revealed that atherosclerosis is a persistent low-grade inflammatory disease with an autoimmune element. One of the most well-known concepts in atherosclerosis is the oxidative modification theory. The critical significance of LDL oxidation and the development of oxidized low-density lipoprotein (Ox-LDL) has been acknowledged in this concept [4]. Oxidative stress is instrumental in the onset and development of atherosclerotic cardiovascular diseases. This disorder is characterized by excessive generation of reactive oxygen species (ROS) and Ox-LDL. Oxidative stress occurs when the generation of free radicals exceeds the ability of the body's antioxidant systems to neutralize them [2].

Traditionally, hyperlipidemia, in combination with other cardiovascular risk factors such as unhealthy diet, smoking, sedentary lifestyle, and hypertension, contributes to endothelial injury and dysfunction. This dysfunction, characterized by elevated vascular permeability and increased expression of adhesion and chemotactic molecules, facilitates the infiltration of LDL particles into the arterial wall, where they are retained through interactions between apolipoprotein B-100 (apo B-100) and extracellular matrix (ECM) proteoglycans. The presence of oxLDL encourages endothelial dysfunction, including vasoconstriction and leukocyte adhesion, stimulates vascular smooth muscle cell dysfunction, including proliferation, migration, and phenotypic switching, elicits macrophage dysfunction, including foam cell formation and inflammasome activation, and induces platelet activation [4]. Antibodies targeting LDL and other atherosclerosis-related antigens are key clinical indicators of autoimmune activity in atherosclerosis. Low-affinity natural antibodies that target oxidation epitopes on LDL are inversely correlated with the development of atherosclerosis, whereas high-affinity antibodies produced by IgG-secreting plasma cells are positively associated with disease progression [3].

The limitations and high costs associated with conventional synthetic drugs have encouraged the exploration of alternative therapies, including herbal drugs, nutritional supplements, and antioxidants, which are typically linked to reduced adverse effects in the management of atherosclerosis. Given that reactive oxygen species (ROS) and oxLDL play pivotal roles in the progression of this condition, the use of antioxidants presents a rational therapeutic approach to prevent or slow the development of atherosclerosis. Sea cucumbers are widely acknowledged as an excellent source of both nutritional and therapeutic substances. This value stems from their wide variety of bioactive components, including saponins, minerals, vitamins, chondroitin sulfates, fatty acids, amino acids, bioactive collagen peptides, and various other beneficial biomolecules [5].

Golden sea cucumbers, also referred to as *Stichopus hermanii*, belong to the Holothuroidea class and phylum Echinodermata. They are pronounced as gamat in Malaysia and teripang emas in Indonesia. *Stichopus hermanii* is commonly misidentified as *Stichopus variegatus* because of their similar physiological characteristics [5]. The golden sea cucumber is distributed in the seas of Sumatra, Nusa Tenggara and Sulawesi. This elongated, cylindrical, and mushy species is a deposit feeder and sedentary marine life that relies on tentacles to capture food on the seabed, with its native habitat comprising hard surfaces, rocks, or shallow seas with dense seagrass. *Stichopus hermanii* often lives in groups of 3–10 and is frequently found in sandy or muddy environments at depths ranging from 1 to 40 m [6].

The majority of golden sea cucumbers are refined into exquisite beche-de-mer cuisine, similar to other highly valued species in their family. Furthermore, they have been progressively explored and developed as traditional medicines over the last decade [5]. The antimicrobial, antiviral, antitumor, antifungal, antioxidant, wound healing, anti-proliferation, immunomodulatory, anticoagulant, antithrombotic, anti-malaria, anti-arthritis, and cholesterol-lowering properties of *Stichopus hermanii* extracts have been demonstrated [6]. In these several studies, there is still limited experimental evidence regarding the anti-inflammatory effect of *Stichopus hermanii* on IL-6 in atherosclerosis models.

Among these inflammatory mediators, interleukin-6 (IL-6) plays a central role. IL-6 is an immune-mediated pro-inflammatory cytokine that is elevated in systemic inflammatory states. IL-6 plays a direct role in activating endothelial monocytes and macrophages, thereby accelerating plaque accumulation and atherosclerosis. Elevated levels of circulating IL-6 have consistently been associated with a higher risk of atherosclerotic cardiovascular disease (CVD) events and all-cause mortality in both patients with existing atherosclerotic CVD and apparently healthy individuals [7]. IL-6 plays a central role in the pathophysiology of various diseases, particularly cancer and atherosclerosis. Atherosclerosis also exhibits significant involvement of IL-6 in its pathogenesis. IL-6 contributes to endothelial dysfunction and fosters a proinflammatory state within the vascular system. Its role in promoting human endothelial cell and monocyte

adhesion further elucidates its contribution to the development of atherosclerotic lesions [8]. Recent evidence has shown the importance of IL-6 in initiating inflammatory processes in atherosclerotic plaque formation and the effects of ox-LDL on IL-6 release. Studies have shown the ability of oxidized LDL to induce IL-6 secretion from monocytes, hepatocytes, and mesangial cells in cell culture. In addition, IL-6 has been found in atherosclerotic plaques [9].

Given its central role in linking oxidative stress, immune activation, and vascular inflammation, IL-6 was selected as the primary biomarker to assess the anti-inflammatory potential of *Stichopus hermanii* extract in a high-fat diet-induced rat model of inflammation. We hypothesized that the administration of *Stichopus hermanii* extract would reduce IL-6 levels, reflecting its potential to mitigate inflammation-related pathways in early atherosclerosis. This study aimed to identify the effects of *Stichopus hermanii* extract on IL-6 levels in a rat model of atherosclerosis induced by a high-fat diet.

## ▪ MATERIALS AND METHODS

### Study design

This true experimental study was conducted in the Biochemistry Laboratory of the Faculty of Medicine at Hang Tuah University, Surabaya, Indonesia. A post-test-only control group design was used in this experiment. Using this methodology, we aimed to accentuate the internal validity of the study to control for confounding circumstances. In this causal study design, the control and treatment groups were compared to validate the hypotheses.

### Population and sample

Federer's method was used to estimate the minimum sample size using the formula:  $(t - 1)(r - 1) \geq 15$  where  $t$  is the number of treatment groups and  $r$  is the number of animals per group. With four experimental groups ( $t = 4$ ), the calculation is as follows:

$$(4 - 1)(r - 1) \geq 15 \Rightarrow 3(r - 1) \geq 15 \Rightarrow r - 1 \geq 5 \Rightarrow r \geq 6$$

Thus, the minimum required sample size was six animals per group, or 24 rats in total. To enhance reliability and account for potential dropouts during the experimental period, the number was increased to eight animals per group, resulting in a total of 32 rats being used. We implemented random selection and assignments. Participants were recruited via simple random sampling and assigned via simple randomization. This study was conducted using an intention-to-treat approach. We selected 32 healthy white Wistar rats (*Rattus norvegicus*) weighing 100-200 g and aged 9-12 weeks. The animals exhibited clear ocular surfaces without discharge, well-maintained coat conditions, normal locomotor activity, and regular bowel habits with normal stool consistency. During the adaptation phase, subjects who died or had a reduced appetite were considered drop-outs.

The rats were fed a high-fat diet and assessed for shifts in IL-6 levels following administration of various doses of *Stichopus hermanii* extract. The species, weight, age, and physical condition of the individuals were homogenized. The participants' nutrition, cage environment, and daily care were controlled. Samples were collected using the defined methods.

### Preliminaries

Before the treatment phase, all individuals experienced a 7-day acclimatization period to adjust to the laboratory environment. They were provided regular feed and distilled water (aquadest) ad libitum. Each rat was housed individually in a 40 × 30 × 15 cm cage with sufficient lighting and ventilation, placed in a quiet area protected from direct sunlight to allow free movement, and minimize stress throughout the study period.

Holothuroidea was recovered for the investigation. The golden sea cucumbers were rinsed with running water and dissected longitudinally along the natural axis of the species. The internal organs were removed, and the remaining tissues were dried on blotting sheets. The dried tissues were then pulverized. A 50 g sample of *Stichopus hermanii* was added to 100 ml of distilled water (aquadest) in a 250 ml conical flask. A water bath shaker (Memmert WNB Series, Germany) was used to mix the mixture at 80 rpm for 4 h at room temperature. The mixture was then centrifuged using a centrifuge (Hettich Rotina 420, Germany) at 3000 rpm for 20 min prior to the freeze-drying process using a laboratory freeze dryer (Labconco, USA).

The dyslipidemia diet was composed of a 500 g standard diet combined with 100 cc of pig oil. The diet was prepared weekly and stored at 24°C. An average of 13,300 g of a high-fat diet was provided weekly. The following diet preparation began when the diet supply began to decrease.

## Experiment

Thirty-two Wistar rats were randomly allocated into four equal groups, each subjected to distinct treatments: (1) the negative control group (E-) received only a standard diet and distilled water orally twice daily for 28 consecutive days, (2) the positive control group (E+) was given a high-fat diet and distilled water orally twice daily for the same duration, (3) experimental group 1 (E1) was administered a high-fat diet and distilled water twice daily, along with *Stichopus hermannii* extract delivered once daily via a gastric tube at a dosage of 35 mg per 200 g body weight for 28 days, and (4) experimental group 2 (E2) received a high-fat diet and distilled water twice daily, with *Stichopus hermannii* extract administered via a gastric tube at a dosage of 40 mg per 200 g body weight once daily for 28 days. The human dosage of *Stichopus hermannii* was converted to determine the experimental dose. The recommended dosage of golden sea cucumbers is 10.5–12 g per 60 kg of body weight. Assuming that the rats weighed 200 g, the derived conversion dosages were 35 mg and 40 mg per 200 g of body weight.

The selection of *Stichopus hermannii* extract doses (35 and 40 mg per 200 g body weight) was based on the conversion of the recommended human consumption dose (10.5–12 g per 60 kg body weight) into an equivalent animal dose. The two doses were chosen to represent low and high therapeutic ranges within a safe and biologically relevant window. Nevertheless, the relatively narrow dose interval may limit the ability to fully characterize the dose–response relationship. Future studies are warranted to include a wider range of doses to better elucidate the pharmacological profile and dose-dependent effects of the extracts.

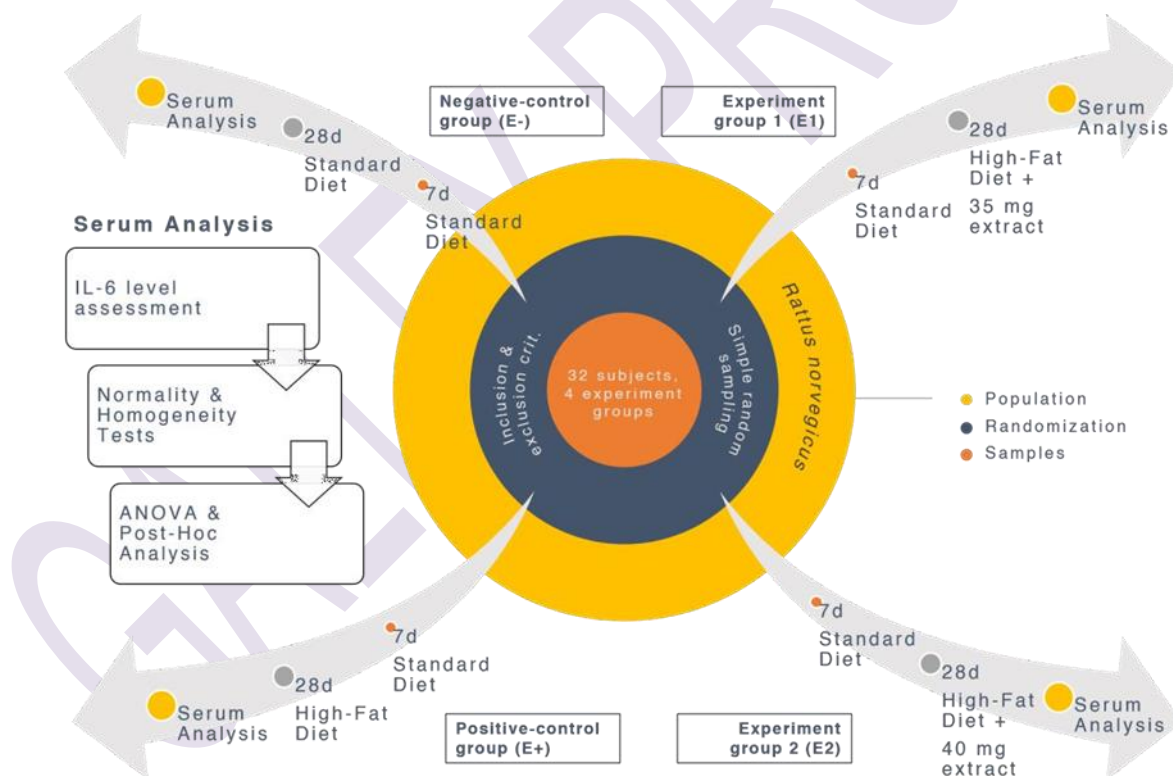


Figure 1. Subject randomization, allocation, and treatment were performed.

## Serum analysis

Before the extraction, the subjects fasted for 12 hours. Water intake was also permitted. After 36 days of manipulation, 7 days of adaptation, and 28 days of treatment, all the subjects were anesthetized using 40–80 mg/kg ketamine (Ketalar, Pfizer, USA) via intramuscular injection. The head and extremities of the subjects were fixed, and anesthesia was injected into the posterior leg using a 33-gauge syringe. The subjects were

placed in a cage until they reached a state of coma. The plantar reflex was evaluated to confirm the effectiveness of anesthesia. Once anesthetized, the subjects were positioned supine, and dissection was performed over the coronal region using a scalpel. Serum was retrieved with a squirt through a perpendicular puncture to the subjects' hearts. Three milliliters of serum was extracted and transferred to a non-anticoagulant tube using a separator tube (Vacutainer; BD, Franklin Lakes, NJ, USA) for prompt testing of IL-6 levels.

The serum started to separate after approximately 1 h at room temperature. A serum separator was used to centrifuge the serum for 15 min at 3450 rpm. The supernatant was collected using a pipette and centrifuged for 10 min at 3450 rpm. The second supernatant was analyzed for IL-6 levels using an enzyme-linked immunosorbent assay (ELISA) kit (Elabsience, USA) [7]-[8].

### Statistical analysis

The levels of IL-6 were classified as continuous variables. We confirmed the statistical assumptions of normality and homogeneity of variance before performing statistical tests on our continuous variables and outcomes. The Shapiro-Wilk test was employed to verify the normal distribution based on the sample size. Data were collected using the mean, median, mode, and standard deviation. To ensure the equivalence of distribution between the study groups, the homogeneity of variance was assessed using Levene's test. If the  $p$ -value was greater than 0.05, normality and homogeneity of variance were assumed.

Four independent groups were compared using continuous variables. Statistical analysis was performed using parametric statistics, considering the normality and homogeneity of variance of the data taken into account. Data were analyzed using one-way analysis of variance (ANOVA). A  $p$ -value < 0.05 was considered statistically significant, indicating a meaningful difference among the independent groups. When ANOVA results showed significance, post-hoc tests were conducted to determine which specific group comparisons accounted for the observed differences. The Bonferroni correction was applied to adjust for multiple comparisons between groups. All statistical analyses were performed using IBM SPSS Statistics (version 25.0).

In addition to inferential statistical testing, an effect size analysis was performed to quantify the magnitude of the differences between the groups. Cohen's  $d$  was calculated for pairwise comparisons using the standard formula:

$$d = \frac{M_1 - M_2}{SD_{pooled}} \quad \text{where} \quad SD_{pooled} = \sqrt{\frac{(n_1 - 1)SD_1^2 + (n_2 - 1)SD_2^2}{n_1 + n_2 - 2}}$$

Each group consisted of eight independent subjects, and duplicate measurements were analyzed as separate datasets to assess reproducibility. Effect sizes were interpreted using conventional thresholds: small (0.2), moderate (0.5), and large ( $\geq 0.8$ ). The inclusion of effect size analysis was intended to complement post hoc testing by providing an estimate of the magnitude of the differences independent of the sample size.

### Ethical statement

The Ethics Committee of the Faculty of Medicine at Hang Tuah University approved the ethical clearance for this study (reference no. I/069/UHT.KEPK.03/VII/2019) in July, 2019.

## RESULTS

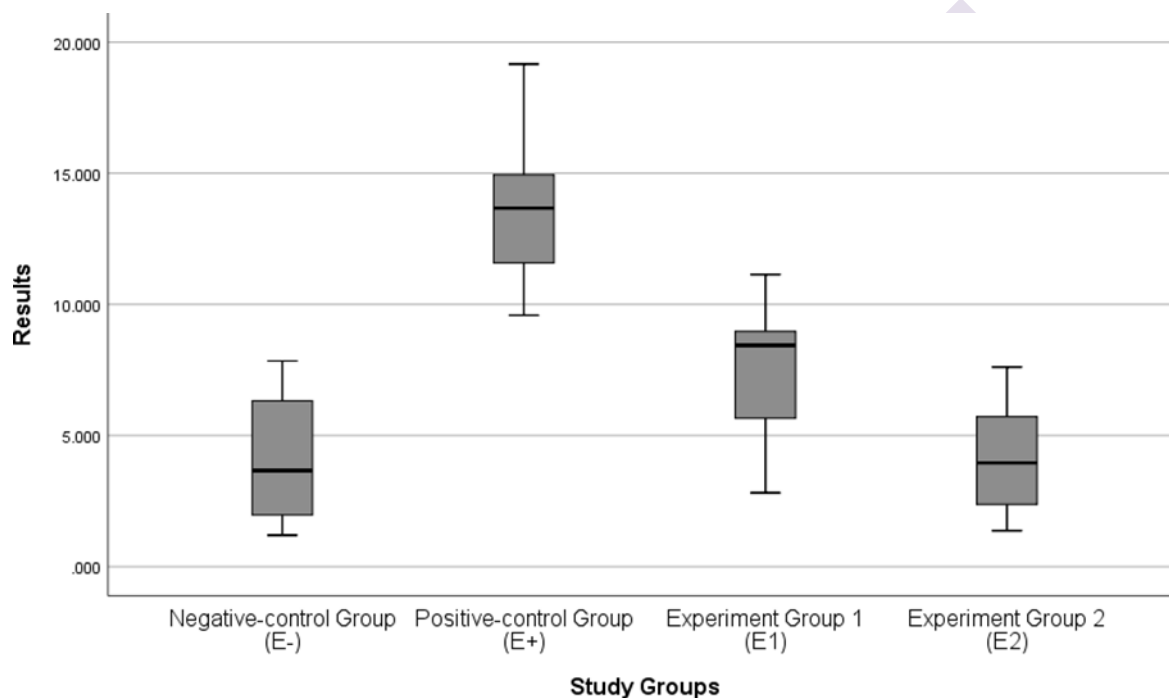
The descriptive analysis findings provided in Table 1 revealed that subjects fed with a high-fat diet had higher IL-6 levels than subjects fed with a regular diet. The subjects in groups E1 and E2, which received the *Stichopus hermanii* extract, demonstrated lower circulating IL-6 concentrations than the positive control group (E+), which was maintained on the same high-fat diet.

Specifically, the IL-6 level in the E1 group was reduced by approximately 50% compared to that in the positive control group. Moreover, the E2 group, which received the highest dose of *Stichopus hermanii* extract, exhibited IL-6 levels comparable to those of the negative control group (E-), which received only a standard diet throughout the experiment.

**Table 1.** Descriptive statistics of interleukin-6 levels.

	E-	E+	E1	E2
Mean±SD	4.12±2.51	13.64±3.02	7.51 ± 2.64	4.14±2.24
[95% CI]	[2.02-6.22]	[11.11-16.16]	[5.30-9.72]	[2.26-6.01]
Median	3.66	13.67	8.44	3.96
[min-max]	[1.20-7.84]	[9.58-19.16]	[2.81-11.14]	[1.38-7.60]
IQR	5.01	4.20	3.65	4.25

SD=standard deviation; CI=confidence interval; min=minimum value; max=maximum value; IQR=interquartile range; E-=negative-control group; E+=positive-control group; E1=experiment group 1; E2=experiment group 2.

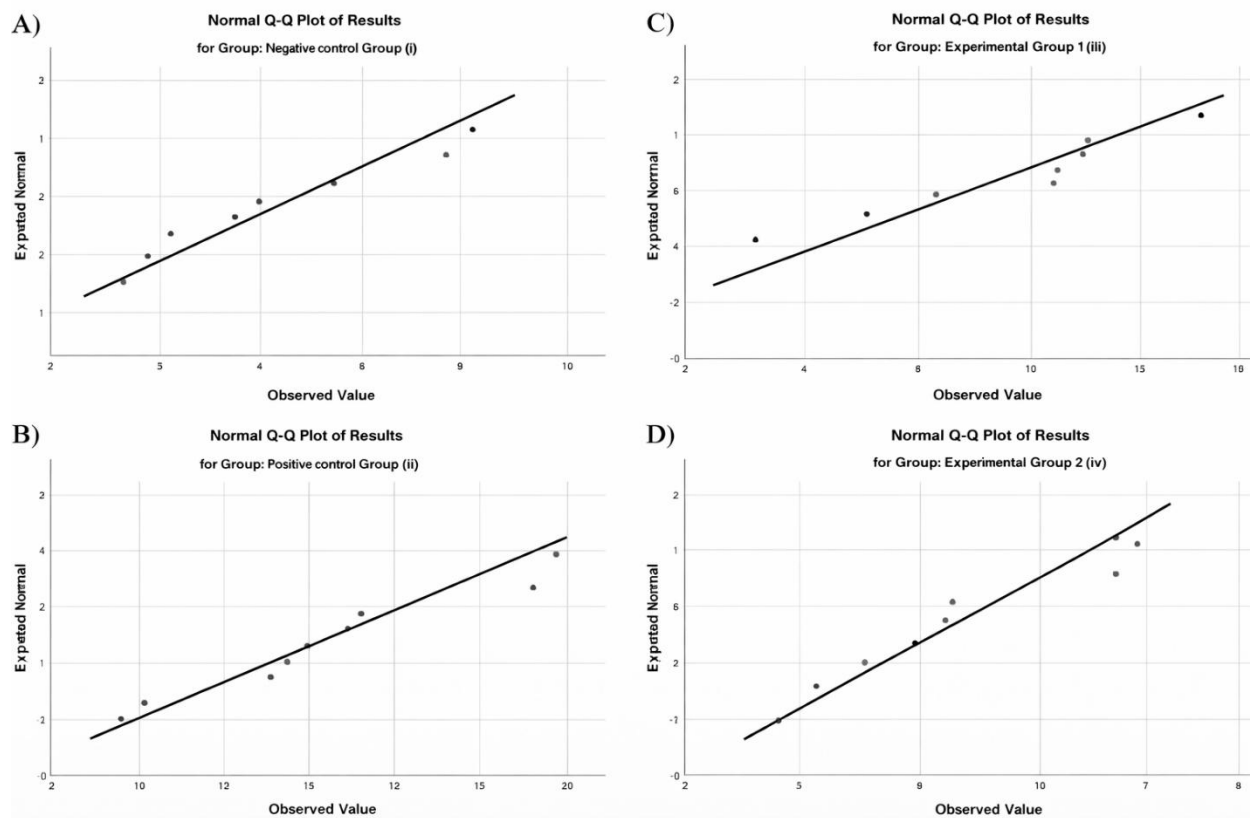
**Figure 2.** Comparison of interleukin-6 levels between the study groups.

The Shapiro-Wilk test demonstrated the assumption of normality in each study group. The normality test revealed that each study group had a normal distribution ( $p>0.05$ ), as shown in Table 2 and Fig 3. Levene's test revealed that homogeneity of variance was present between each of the study groups ( $p>0.05$ ). Given the normality and homogeneity of variance of the study, parametric statistics one-way ANOVA was used to quantify the causality effects between these independent groups. The ANOVA results revealed significant differences across the various treatments provided in each study group ( $p<0.001$ ).

**Table 2.** Normality, homogeneity of variance, and analysis of variance of interleukin-6 levels.

Study groups	p-value		
	Shapiro-wilk test	Levene's test	ANOVA
Negative-control group (E-)	0.398	0.938	<0.001
Positive-control group (E+)	0.531		
Experiment group 1 (E1)	0.575		
Experiment group 2 (E2)	0.440		

ANOVA=analysis of variance.



**Figure 3.** Q-Q plot of the distribution of interleukin-6 levels in each study group.

Table 3 illustrates that the post-hoc analysis identified multiple significant differences among the research groups. IL-6 concentrations were significantly elevated in the positive control group compared to those in the negative control group, confirming the successful induction of dyslipidemia through the high-fat diet as opposed to the standard diet. In contrast, both experimental groups exhibited significantly lower IL-6 levels than the positive control group, even at lower extract dosages. The magnitude of these differences was significant, supporting the meaningful biological effect of *Stichopus hermanii* on systemic inflammation. Furthermore, no statistically significant difference in IL-6 concentration was observed between the negative control and experimental groups. However, the comparison between E- and E1 showed a numerical reduction in IL-6 that did not reach statistical significance ( $p = 0.091$ ), suggesting a trend toward improvement that may have been limited by sample size and inter-individual variability. Notably, IL-6 levels in the group receiving the higher dose of *Stichopus hermanii* extract were comparable to those in the negative control group. Simultaneously, the difference between E1 and E2 was not statistically significant ( $p = 0.094$ ), indicating that the higher dose may not have produced a clearly distinguishable additional benefit over the lower dose, although the direction of change still favored the higher dose.

Table 3. Post-hoc analysis of interleukin-6 levels.

Matched Study Groups		CI	p-value
a	b		
	Positive-control group (E+)	-9.52 [-13.24 - -5.80]	<0.001
Negative-control group (E-)	Experiment group 1 (E1)	-3.39 [-7.11 - 0.32]	0.091
	Experiment group 2 (E2)	-0.01 [-3.73 - 3.70]	1.000
	Negative-control group (E-)	9.52 [5.80 - 13.24]	<0.001
Positive-control group (E+)	Experiment group 1 (E1)	6.13 [2.40 -9.85]	<0.001
	Experiment group 2 (E2)	9.50 [5.78 - 13.22]	<0.001
	Negative-control group (E-)	3.39 [-0.32 - 7.11]	0.091
Experiment group 1 (E1)	Positive-control group (E+)	-6.13 [-9.85 - -2.40]	<0.001
	Experiment group 2 (E2)	3.37 [-0.34 - 7.09]	0.094

CI=confidence interval.

Effect size analysis demonstrated consistently large to very large differences across all the key comparisons (Table 4). The induction of inflammation by a high-fat diet resulted in an extremely large effect when comparing the positive and negative control groups (Cohen's  $d \approx -3.563$  across duplicate datasets), confirming robust model establishment. Treatment with *Stichopus hermanii* extract produced marked reductions in IL-6 levels, with large to very large effect sizes observed for both 35 mg/kg ( $d \approx -2.269$ ) and 40 mg/kg ( $d \approx -3.730$ ) when compared with the positive control. A comparison between treatment doses revealed a large effect size ( $d \approx -1.376$ ) in both duplicate datasets, indicating a meaningful difference despite the absence of statistical significance in the post hoc analysis. Notably, the highest dose (40 mg/kg) yielded negligible effect size differences relative to the negative control ( $d \approx 0.27$ ), indicating near-complete normalization of IL-6 levels, whereas the lower dose substantially elevated it ( $d \approx 1.293$ ).

Table 4. Effect size analysis of interleukin-6 levels using Cohen's d.

Matched study groups		d [95% CI]
a	b	
	Positive-control group (E+)	-3.563 [-5.173 - -1.908]
Negative-control group (E-)	Experiment group 1 (E1)	-1.293 [-2.363 - -0.185]
	Experiment group 2 (E2)	0.27 [-0.953 - 1.007]
Positive-control group (E+)	Experiment group 1 (E1)	2.269 [0.960 - 3.531]
	Experiment group 2 (E2)	3.730 [2.025 - 5.389]
Experiment group 1 (E1)	Experiment group 2 (E2)	1.376 [0.255 - 2.459]

## DISCUSSION

Inflammation is a central component of atherosclerosis, particularly in the context of metabolic stress induced by a high-fat diet [10],[11],[12]. Rather than representing a single downstream marker, interleukin-6 (IL-6) occupies a strategic position within the inflammatory cascade, acting as a key intermediary between upstream innate immune activation, such as inflammasome-driven interleukin-1 $\beta$  signaling, and downstream systemic responses, including hepatic acute-phase protein production [10],[11],[13]. This biological positioning gives IL-6 both mechanistic relevance and translational value as a surrogate marker of systemic inflammatory activation in cardiometabolic diseases [13],[14]. Accordingly, the present study specifically focused on IL-6 to evaluate whether *Stichopus hermanii* extract modulates this central inflammatory axis in a diet-induced model.

The principal finding was that the administration of *Stichopus hermanii* extract significantly reduced circulating IL-6 levels in a dose-responsive pattern, with the highest dose restoring IL-6 concentrations to levels comparable to those in the negative control group. This effect suggests a biologically meaningful attenuation of systemic inflammatory signaling rather than a marginal statistical difference. Given the established association between elevated IL-6 levels and increased atherosclerotic burden and plaque instability, this finding supports the hypothesis that *Stichopus hermanii* may exert anti-inflammatory effects within the context of metabolic inflammation [13], [15].

It is important to emphasize that this study was designed to isolate and examine the IL-6-mediated inflammatory pathway rather than provide a comprehensive assessment of atherosclerotic disease progression. Other metabolic and oxidative stress parameters, including the lipid profile and markers of oxidative injury, were evaluated within the broader experimental framework but were reported separately to allow a more focused analysis of inflammatory signaling. This approach enables a clearer interpretation of pathway-specific effects, although it necessarily limits direct conclusions regarding the integrated impact on atherogenesis.

The observed reduction in IL-6 levels is consistent with the known bioactive composition of *Stichopus hermanii*, which includes glycosaminoglycans, omega-3 fatty acids, saponins, flavonoids, and collagen-derived peptides [6], [16]. These compounds have been associated with both anti-inflammatory and antioxidant properties in previous studies. In particular, saponins and related marine-derived bioactives have demonstrated the ability to downregulate proinflammatory cytokines, such as IL-6 and tumor necrosis factor- $\alpha$ , as well as modulate macrophage polarization and endothelial activation [17]. The present findings extend this body of evidence by demonstrating that these effects are observable in a chronic, diet-induced inflammatory model, which more closely reflects the low-grade systemic inflammation observed in early cardiometabolic diseases than acute inflammatory models.

The novelty of this study lies not only in demonstrating cytokine reduction but also in showing that *Stichopus hermanii* extract modulates IL-6-associated inflammatory signaling within a high-fat diet-induced model of metabolic inflammation, reflecting early pro-atherogenic inflammatory processes rather than established atherosclerotic disease [11], [18]. Additionally, the dose-dependent pattern observed suggests a pharmacologically plausible effect, although the absence of statistically significant differences between intermediate and high doses indicates that the response may begin to plateau within the tested range of doses.

Despite these findings, several limitations of this study must be considered. First, the use of IL-6 as a single inflammatory marker, while mechanistically justified, does not capture the full complexity of the inflammatory network involved in atherosclerosis [10] [11]. Additional cytokines (e.g., IL-1 $\beta$  and TNF- $\alpha$ ), adhesion molecules, and downstream markers, such as C-reactive protein, would provide a more comprehensive assessment of inflammatory modulation. Second, the absence of concurrently presented lipid profiles, oxidative stress markers, and histopathological evaluation of vascular tissue in this report limits the ability to directly link IL-6 reduction with structural or functional improvements in atherosclerotic disease. Third, the study was conducted in an animal model; therefore, the findings should be interpreted as preclinical evidence of biological activity rather than as an indication of clinical efficacy. Fourth, the sample size may have limited the statistical power to fully resolve dose-response relationships, as suggested by the non-significant differences between the treatment groups despite observable numerical trends.

In conclusion, the present study demonstrates that *Stichopus hermanii* extract reduces IL-6 levels in a high-fat diet-induced model of metabolic inflammation, supporting its potential role as a modulator of systemic inflammatory signaling. However, further studies incorporating broader inflammatory panels, lipid parameters, and direct vascular outcomes are required to determine whether these anti-inflammatory effects translate into meaningful anti-atherogenic benefits in patients with diabetes.

## CONCLUSION

A high-fat diet was associated with increased IL-6 levels compared to that of a standard diet. Administration of *Stichopus hermanii* extract resulted in a reduction of IL-6 levels in the treated groups compared to the positive control group, with the higher dose showing levels comparable to the negative control group. These findings indicate that *Stichopus hermanii* extract exerts an anti-inflammatory effect, as

reflected by the modulation of IL-6 levels in a high-fat diet-induced rat model. However, as this study evaluated only a single inflammatory biomarker, further investigations incorporating additional parameters are required to comprehensively assess the broader biological and potential cardioprotective effects of the *Stichopus hermanii* extract.

**Acknowledgements:** We extend our sincere gratitude to the Faculty of Medicine, Hang Tuah University and Lembaga Penelitian dan Pengabdian kepada Masyarakat (LPPM), Hang Tuah University for supporting this study.

**Funding:** This study was supported by the Faculty of Medicine, Hang Tuah University, Surabaya, Indonesia.

**Conflict of interest statement:** The authors declare no conflicts of interest.

## REFERENCES

- [1] World Heart Federation, *World Heart Report 2023: Confronting the world's number one killer*. Geneva: World Heart Federation, 2023.
- [2] K. Malekmohammad, R. D. E. Sewell, and M. Rafieian-Kopaei, "Antioxidants and atherosclerosis: mechanistic aspects," *Biomolecules*, vol. 9, p. 301, 2019, doi: 10.3390/biom9080301.
- [3] D. Wolf and K. Ley, "Immunity and inflammation in atherosclerosis," *Circ. Res.*, vol. 124, no. 2, pp. 315–327, 2019, doi: 10.1161/CIRCRESAHA.118.313591.
- [4] S. Zhang, L. Li, W. Chen, S. Xu, X. Feng, and L. Zhang, "Natural products: The role and mechanism in low-density lipoprotein oxidation and atherosclerosis," *Phytother. Res.*, vol. 35, no. 6, pp. 1–23, 2020, doi: 10.1002/ptr.7002.
- [5] Y. N. Fawzya, N. A. Putra, A. B. Witarto, and G. Patantis, "Golden Sea cucumber: identification and the antioxidant activity of its collagen hydrolysates," *SQUALEN Bull. Mar. Fish. Postharvest Biotechnol.*, vol. 15, no. 3, p. 119, 2020, doi: 10.15578/squalen.v15i3.511.
- [6] D. Pringgenies, S. Rudiyaniti, and E. Yudiati, "Exploration of sea cucumbers *stichopus hermanii* from Karimunjawa Islands as production of marine biological resources," *IOP Conf. Ser. Earth Environ. Sci.*, vol. 116, no. 1, p. 012039, 2018, doi: 10.1088/1755-1315/116/1/012039.
- [7] M. Khan et al., "Interleukin-6 and cardiovascular events in healthy adults," *JACC Adv.*, vol. 3, no. 8, p. 101063, 2024, doi: 10.1016/j.jacadv.2024.101063.
- [8] R. Cau and L. Saba, "Interlinking pathways: a narrative review on the role of IL-6 in cancer and atherosclerosis," *Cardiovasc. Diagn. Ther.*, vol. 14, no. 6, pp. 1186–1201, 2024, doi: 10.21037/cdt-24-344.
- [9] A. Ghadiri-anari, J. Behjati, A. Esteghamati, F. Esfahanian, Z. Khazaiipoor, and M. Nakhjavani, "Correlation between oxidized-LDL and interleukin-6 in type 2 diabetic patients," *Iran. J. Diabetes Lipid Disord.*, vol. 10, pp. 1–7, 2011.
- [10] S. Kim and Y. Jang, "Inflammation in Atherosclerotic cardiovascular diseases: Biomarkers to therapeutics in clinical settings," *J. Cardiovasc. Interv.*, vol. 3, no. 4, pp. 199–215, 2024, doi: 10.54912/jci.2024.0014.
- [11] P. Libby, "Inflammation and the pathogenesis of atherosclerosis," *Vascul. Pharmacol.*, vol. 154, p. 107255, 2024, doi: 10.1016/j.vph.2023.107255.
- [12] Y. Zhu et al., "Research progress on the relationship between atherosclerosis and inflammation," *Biomolecules*, vol. 8, no. 3, p. 80, 2018, doi: 10.3390/biom8030080.
- [13] N. N. Mehta, E. DeGoma, and M. D. Shapiro, "IL-6 and cardiovascular risk: A narrative review," *Curr. Atheroscler. Rep.*, vol. 27, p. 12, 2025, doi: 10.1007/s11883-024-01259-7.
- [14] E. V Gerasimova, T. V Popkova, I. G. Kirillova, D. A. Gerasimova, E. L. Nasonov, and A. M. Lila, "Interleukin-6: cardiovascular aspects of long-term cytokine suppression in patients with rheumatoid arthritis," *Int. J. Mol. Sci.*, vol. 25, p. 12425, 2024, doi: 10.3390/ijms252212425.
- [15] G. K. Hansson, P. Libby, and I. Tabas, "Inflammation and plaque vulnerability," *J. Intern. Med.*, vol. 278, no. 5, pp. 483–493, 2016, doi: 10.1111/joim.12406.Inflammation.
- [16] D. W. Damaiyanti, "Characterization of water extract gold sea cucumber (*Stichopus hermanii*)," *Dent. J. Kedokt. Gigi*, vol. 9, no. 1, pp. 74–81, 2015.
- [17] L. Ding et al., "Saponins of sea cucumber attenuate atherosclerosis in ApoE<sup>-/-</sup> mice via lipid-lowering and anti-inflammatory properties," *J. Funct. Foods*, vol. 48, pp. 490–497, 2018, doi: 10.1016/j.jff.2018.07.046.

- [18] D. A. Chistiakov, A. A. Melnichenko, A. V Grechko, V. A. Myasoedova, and A. N. Orekhov, "Potential of anti-inflammatory agents for treatment of atherosclerosis," *Exp. Mol. Pathol.*, vol. 104, no. 2, pp. 114-124, 2018, doi: 10.1016/j.yexmp.2018.01.008.

GALLEY PROOF